

Anterior Cervical Corpectomy and the Operating Team: A Controversy?

Alexandrina Nikova¹ Theodossios Birbilis¹

¹Department of Neurosurgery, Democritus University of Thrace, Alexandroupolis, Greece

Address for correspondence Alexandrina Nikova, Department of Neurosurgery, Democritus University of Thrace, Dragana 68100, Alexandroupolis, Greece (e-mail: nikovaalex@gmail.com).

Indian J Neurosurg 2018;7:8–15

Abstract

Cervical myelopathy is multifactorial disease that can lead to many dysfunctions. Surgical treatment is believed to be the best healing choice. The authors searched the published data on Medline on this subject and found a difference between the neurosurgeons and orthopaedics on the topic of anterior corpectomy for cervical myelopathy. The difference between the orthopaedics and neurosurgeons is not big, but it could be relevant to the final outcome, which appears to be better in the neurosurgeons. The complication rate is also variable between the groups, with lower rates of complication reported by the neurosurgeons. Therefore, despite the fact that the postoperative outcome depends on many factors, such as preoperative condition, additional comorbidities, age, and lifestyle, this article also finds that the surgical team, after comparing basic techniques that the team used for anterior cervical corpectomy (ACC), is also responsible to some extent. This, however, is not a competition, and future cooperation between the teams might be beneficial for all.

Keywords

- ▶ cervical myelopathy
- ▶ improvement
- ▶ outcome
- ▶ surgery
- ▶ quality of life

Introduction

Cervical myelopathy (CM) was first introduced to the scene of pathology of the cervical spine by Lees and Turner and by Clarke and Robinson.¹

CM is indeed a progressive pathologic state based on reduction in the spinal canal followed by cord dysfunction and, in some cases, paralysis. It is linked to spinal cord compression or ischemia and degenerative changes. As a result, there is an injury to the spinal cord, of the vascular and nerve function. Because of that, those patients' quality of life is observed to decrease constantly without management.

Proper therapy and enhancement of the quality of life are believed to be achieved with surgery, and for this reason, the reviewers aspire to show that the operating team plays a role for the postoperative outcome of those patients.

Methods

The researchers chose this subject because of the controversial interest that stems from it, as well as the lack of information. The topic, whether orthopaedics or neurosurgeons or both, have better results, and the percentage of complication

of each team after corpectomy for CM triggered the initiative to search the published data on Medline. For the analysis, the authors collected published studies between 1991 and 2017 with Mesh terms “cervical myelopathy,” “neurosurgeons,” “orthopaedics,” “corpectomy,” and “anterior spine surgery.” The studies encompass all kinds of age categories, including elderly patients and patients with comorbidities (diabetes, cardiac problems, etc.) and single or/and multilevel CM.

Inclusion criteria for the study were articles on humans; articles written in English; articles providing information on the technique of the corpectomy and, if there are complications, the publishing team to be only from one kind of department—neurosurgery or orthopaedics—and finally articles with improvement rate based on Japanese Orthopedic Association (JOA) score. After the search, the authors included 47 articles with the aforementioned criteria (23 neurosurgeons and 24 orthopaedics) (▶ **Tables 1, 2**, ▶ **Fig. 1**).

On the other hand, the reviewers excluded letters to editor; comments; case reports; animal trials; articles without abstracts; multicenter studies; most of the reviews and meta-analyses; articles in other than English language; articles that do not show the complications, and/or the

received

December 15, 2017

accepted after revision

March 23, 2018

published online

May 15, 2018

DOI <https://doi.org/>

10.1055/s-0038-1651532.

ISSN 2277-954X.

Copyright ©2018 Neurological Surgeons' Society of India

License terms



Table 1 List of studies reported by neurosurgeons

Team	No. of patients	Technique	Improvement rate (%)
Za'iri et al ¹²	26	Titanium cage, plate, bone graft from the corpectomy; ACCF	100
Acosta et al ¹³	20	ACCF; cage, plate, corpectomy graft, or allograft	83
Shaker et al ¹⁴	26	Oblique corpectomy	76.9
Koc et al ¹⁵	44	ACCF; iliac graft and plate	88.6
Thakar et al ¹⁹	67	Central corpectomy; plate and iliac graft	88.05
Lee et al ²⁰	22	Oblique	70.81
Chibbaro et al ²¹	70	ACCF; iliac graft, plate, and cage	94.2
Costa et al ²³	34	ACCF; iliac graft and plate	73.3
Rochhi et al ²⁴	48	Oblique corpectomy	85.42
Turel et al ²⁵	28	Oblique corpectomy	97.37
Chang et al ²⁶	15	ACCF; cage and plate	100
Lau et al ³¹	60	ACCF; cage, plate, and graft from the corpectomy	95
Ozer et al ³²	11	Open-window corpectomy; iliac or allograft	100
Duzkalir et al ³⁶	60	Central corpectomy; fibular and iliac graft	100
Epstein ³⁷	48	ACCF; iliac graft or allograft and plate	89
Epstein and Silvergleide ³⁸	46	ACCF; plate and iliac graft	83
Ernestus et al ³⁹	46	Central corpectomy; iliac or corpectomy graft, cage, implants, and plate	93
Perrini et al ⁴¹	42	ACCF; cage, plate, iliac and corpectomy graft	100
Gupta and Rajshekhar ⁴³	33	Central corpectomy; fibula graft	90
Kristof et al ⁵⁰	42	ACCF; iliac graft and plate	79
Kotil and Tari ⁵³	25	ACCF; iliac graft and plate	69
Kumar et al ⁵⁴	410	Central corpectomy; iliac or fibula graft	98
Rajshekhar et al ⁵⁶	60	Central corpectomy; cage, plate, and iliac of fibula graft	100

Abbreviation: ACCF, anterior cervical corpectomy with fusion.

improvement and/or the operative technique; articles from more than one kind of departments or not sufficient operating team, publishing the article; and articles that report improvement based on other than JOA score system. Finally, the authors blindly excluded articles that were last in the row on Medline, to compare approximately the same numbers of studies, because of the insufficient number of papers from the neurosurgeons (not enough articles that meet the inclusion criteria).

Thereafter, the authors analyzed the data with F-test and t-test on Excel.

Surgical Management and Outcome

Treatment of CM is generally divided into operative and nonoperative.^{1,2} Operative treatment is being considered in presence of symptomatic cord dysfunction or pain and earlier operation in case of rapid neurologic deterioration.¹ Studies show that most patients following surgical treatment have an improvement of their functionality.³ There are plenty of surgical options, including anterior and posterior approaches with or without fusion.⁴

The most common posterior technique is laminectomy (LAMT), performed with or without fusion.⁴ Laminoplasty (LAMP), on the other hand, is a posterior approach used to

prevent complications with the disadvantage of axial symptoms after surgery.^{4,5}

On the other hand, anterior approach (corpectomy or discectomy) is thought to have less complications, compared with the posterior approach, and the advantage of straight excision of the pathology, better fusion and reconstruction of deformities, relief of the spinal artery, and neck-pain restoration.^{6,7} Rates of improvement and fusion are the same between corpectomy and discectomy, except the level of complications,^{8,9} whereas other studies report that corpectomy has better general recovery rate than others.¹⁰ Because of this controversy, the authors chose to analyze the cervical corpectomy.

Corpectomy Technique and Rate of Improvement

Regarding the improving rate, the worldwide guidelines¹¹ report that these techniques have similar outcomes. The authors of this study, however, investigating the surgical group for corpectomy suggest that the outcome is highly dependable on the operating team, while the number of patients do not play a major role to the outcome.

Concluding from the reviewed studies, the outcome for CM after surgery is quite promising. The general improving

Table 2 List of studies reported by orthopaedic surgeons

Study	No. of patients	Technique	Improvement rate (%)
Shaker et al ¹⁴	8	ACCF; fibula graft and plate	100
Aramomi et al ¹⁷	9	Anterior pedicle; fibula graft, plate	82.79
Shibuya et al ¹⁸		Subtotal corpectomy; iliac graft	55.5
Ying et al ⁶²	178	Corpectomy with preserved vertebral wall; cage, plate, and iliac graft	76.49
Lin et al ²²	63	ACCF or skip-level corpectomy; cage and plate	93.23
Gao et al ²⁷	145	ACCF; cage, plate, iliac or corpectomy graft	62.5
Huang et al ²⁸	19	ACCF; allograft or corpectomy graft, plate	71.4
Yang et al ²⁹	67	ACCF; cage, plate, corpectomy graft	85.64
Liu et al ³⁰	24	Subtotal corpectomy; iliac graft and plate	67.09
Yan et al ³³	75	ACCF; cage, plate, and corpectomy graft	82.05
Williams et al ¹⁰	24	ACCF; plate, iliac graft	62.35
Fengbin et al ³⁴	58	ACCF; cage, plate, and corpectomy graft	58
Mao et al ³⁵	42	ACCF; cage, plate, and corpectomy graft	86.96
Niu et al ⁴⁰	23	Key hole; allograft or corpectomy graft	83
Li et al ⁴²	39	Segmental ACCF; cage, corpectomy graft, and plate	88.16
Gupta and Rajshekhar ⁴³	15	ACCF; cage, implants, plate, corpectomy graft	81.82
Li et al ⁴⁵	39	Segmental ACCF; iliac graft, cage, and plate	87.1
Liu et al ⁴⁶	28	Hybrid; implant, cage, plate, and corpectomy graft	55.83
Tateiwa et al ⁴⁷	27	Subtotal corpectomy; fibula graft	62
Zhang et al ⁴⁸	117	ACCF; cage, corpectomy graft	90
Wada et al ⁴⁹	23	Subtotal corpectomy; iliac or fibula graft	82.41
Kimura et al ⁵¹	16	ACCF; iliac or fibula graft and plate	78.95
Odate et al ⁵²	42	Hybrid; plate and fibula graft	53.8
Lu et al ⁵⁵	51	ACCF; cage, plate, and corpectomy graft	69.7

Abbreviation: ACCF, anterior cervical corpectomy with fusion.

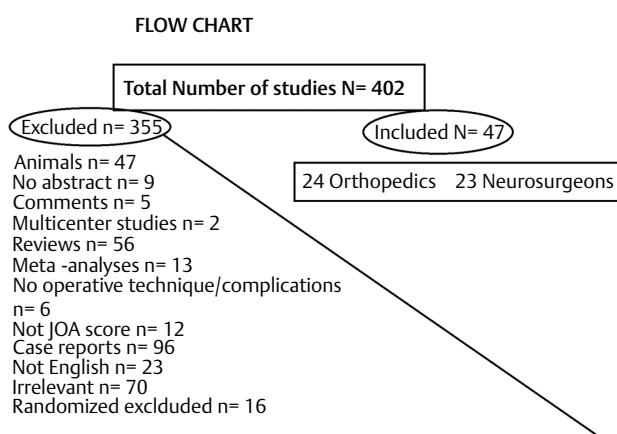


Fig. 1 Flowchart. JOA, Japanese Orthopedic Association.

rate is mainly more than 50% with good fusion rate and improvement of the quality, results comparable to those by the Congress of Neurological Surgeons.¹¹ However, it should be taken into consideration the fact that neurosurgeons have better rate of improvement than the orthopaedics (all of the rates are calculated on the principle: Sum of improving rates/

Number of studies). As it could be seen in ►Table 3–5,^{12–56} the average rate of improvement after corpectomy of the neurosurgeons is 89.56% whereas the same rate for the orthopaedics is 75.95%.

Further analyzation of the techniques shows that orthopaedics use only fusion for the corpectomy with or without instrumentation, whereas some of the neurosurgeons do not. The improving rate after fusion is 89.70% for the neurosurgeons and 75.95% for the orthopaedics. Furthermore, the F-test and *t*-test, as it could be seen in ►Tables 4 and 5, support that the fusion rate of the orthopaedics and neurosurgeons is not equal. The authors performed these tests for the four categories—corpectomy with fusion, fusion with graft only, with cage and plate, and with plate only—and all these showed that these categories are not equal. The fusion is further analyzed, based on the used graft, as is shown in ►Table 6 that shows that fibula autograft fusion has better results in orthopaedics whereas every other autograft or allograft has better results in neurosurgeons.

Finally, as the authors analyzed the technique used for the anterior approach, it seems that the most common technique—anterior cervical corpectomy with fusion

Table 3 Improving rate in orthopaedics and neurosurgery¹²⁻⁵⁶

Criteria	Neurosurgeon Mean value of improvement	Orthopaedics Mean value of improvement
Average improving rate based on JOA score	89.56%	75.95%
Corpectomy with fusion	N ^a = 20 (89.7%)	N = 24 (75.95%)
Corpectomy without fusion	N = 3 (86.56%)	N = 0
Fusion with cage (and plate)	N = 8 (95.65%)	N = 13 (78.74%)
Fusion with plate only	N = 7 (81.42%)	N = 7 (75.08%)
Fusion with screw only	N = 2 (85.41%)	N = 0
Fusion without graft	N = 1 (100%)	N = 0
Fusion with graft only	N = 3 (96%)	N = 4 (70.73%)

Abbreviation: JOA, Japanese Orthopedic Association.

^aN, number of studies.

Note: Mean value of improvement = Sum of the improving rates reported by every study based on JOA score/Number of studies.

Table 4 F-test of corpectomy with fusion

F-test: Two-sample for variances		
	Corpectomy with fusion	Corpectomy with fusion
Mean	89,698	75,94875
Variance	106,7223	187,8816
Observations	20	24
df	19	23
F	0,56803	
P (F≤f) one-tail	0,10721	
F critical one-tail	0,470973	

Table 5 t-test of corpectomy with fusion

t-test: Two-sample assuming unequal variances		
	Corpectomy with fusion	Corpectomy with fusion
Mean	89,698	75,94875
Variance	106,7223	187,8815592
Observations	20	24
Hypothesized mean difference	0	
df	42	
t stat	3,789453	
P (T≤t) one-tail	0,000238	
t critical one-tail	1,681952	
P (T≤t) two-tail	0,000476	
t critical two-tail	2,018082	

(ACCF)—has better improving rate in the neurosurgical group rather than in orthopaedics. ACCF actually means a total incision of the pathology that requires fusion (graft or cage) for spinal stabilization.⁵⁷ Oblique corpectomy, on the other hand, is a technique that does not require grafting

Table 6 Graft techniques and improving rate^{12-56,62}

Fusion with graft technique	Improving rate in neurosurgery (Mean value of improvement, %)	Improving rate in orthopaedics (Mean value of improvement, %)
Iliac autograft only	N = 7 (82.16%)	N = 5 (69.71%)
Fibula autograft only	N = 1 (90%)	N = 2 (91.4%)
Local bone graft or iliac autograft	N = 1 (93%)	N = 0
Local bone graft only	N = 2 (97.5%)	N = 9 (78.2%)
Fibula or iliac autograft	N = 3 (99.33%)	N = 2 (80.68%)
Allograft or other graft	N = 3 (90.67%)	N = 2 (77.2%)
Implants	N = 1 (93%)	N = 2 (68.83%)

Abbreviation: N, number of studies.

Note: Mean value of improvement = Sum of the reported improvements/Number of studies.

but also could not treat bilateral symptomatology.⁵⁸ Central corpectomy is used mainly for ossification of the posterior longitudinal ligament (PLL) and could be accompanied by graft.⁵⁴ As it can be observed in ►Table 7, oblique corpectomy and central corpectomy are techniques adopted by neurosurgeons.

Subtotal corpectomy, as it could be seen, is adopted by the orthopaedic team and represents a partial removal of the vertebral body with fusion.

In the unusual techniques are encompassed hybrid techniques of discectomy and corpectomy, open-window corpectomy, “key hole” technique, and anterior pedicle screw.

All these techniques could be performed with or without a microscope. From the orthopaedic articles, no one reported the use of microscope for the anterior corpectomy, whereas plenty of the neurosurgical articles reported the use of microscope for the operation.

Table 7 Operative technique and improving rate^{12–56,62}

Operative technique	Improving rate in neurosurgeons (Mean value, %)	Improving rate in orthopaedics (Mean value, %)
Oblique corpectomy	82.63%	–
Subtotal corpectomy	–	66.75%
Central corpectomy	94.84%	–
Anterior cervical corpectomy with fusion (ACCF)	87.84%	77.95%
Segmental ACCF	–	87.63%
Unusual techniques	100%	74.19%

Complications

Despite the fact that surgical treatment is prescribed to patients who fulfill the inclusion criteria, many of the patients experience complications. The rate of complication is variable, depending on the patients' characteristics, such as age and other conditions; the surgical technique; and the preexisting condition, and as it stems from this study, it also depends on the surgical team.

Many clinical studies show their complication rates. Saunders et al⁵⁹ report complication rate of 47.5% after corpectomy. For the same approach, Lian et al⁶⁰ show rate of complication rate equal to 16.19% and Perrini et al⁴¹ equal to 15%. Liu et al³⁰ show complication rate of 18.2%. The report of the complications, however, does not necessarily mean that every surgical technique is accompanied with problems. Thakar et al¹⁹ and Chibbaro et al,²¹ for instance, do not report complications after surgery. In this study, four articles from the orthopaedics and five from the neurosurgical team reported “no complications.”

Other authors,⁶¹ after detailed research, report the prevalence of every complication, based on the technique.

Until now, however, no article on Medline reports the complication rate, based on the surgical team. The authors of this study searched every kind of complication separately from the general complication rate and found that the incidence of complications is higher in orthopaedics (Sum of complication rates/Number of studies) (► **Table 8**). A few kinds of complications, however, are more frequent in neurosurgeons.

Complications with higher prevalence of neurosurgeons, reported in a single study from one patient, include bleeding (4.35%), mortality (4.17%), adjacent segment disease (6.3%), hoarseness (7.1%), muscle weakness (3.85%), and kyphosis (3.8%). Most of those kinds of complications are reported in multiple studies by orthopaedic teams, but the mean number is lower than the number in neurosurgeons. Complications with higher prevalence of the neurosurgeons, reported in more than one studies and compared with the orthopaedics, include graft fracture (6.85% neurosurgery, 5.73% orthopaedics), radiculopathy (6.19% neurosurgery, 3.64% orthopaedics), screw back-out (17.79% neurosurgery, 7.32% orthopaedics), and Horner's syndrome (29.93% neurosurgery, 0% orthopaedics, reported by two studies).

Postoperative problems with equivalent mean score include reoperation (7.16% orthopaedics and 7.68% neurosurgeons) and pain (7.7% orthopaedics and 7.7% neurosurgeons).

Table 8 Complications after corpectomy^{12–56,62}

Kind of complication	Neurosurgery (%)	Orthopaedics (%)
Dysphagia	9.19	17.28
Screw loosening		35.5
Enterotropic ossification ^a		10.53
Infection	6.23	7.91
Bone graft displacement/migration	4.75	7.05
Delirium ^a		1.96
Pulmonary embolism	4.35	7.1
CSF leak	2.99	6.02
Pseudoarthrosis	7.92	18.89
Screw extrusion ^a		3.33
Esophagus fistula ^a		4.35
Laryngeal nerve palsy	1.49	4.17
Dural tear ^a		7.14
Hematoma		2.38
Hardware failure		12.5
Respiratory failure		13.57
C5 palsy	7.9	8.42

Abbreviation: CSF, cerebrospinal fluid.

^aReported in single study.

Every other kind of postoperative complication is more frequent among orthopaedics (► **Table 8**). Some of the complications are reported by single studies, but the majority represents an average number.

Concluding to this, orthopaedics have less improvement rate and higher values of the postoperative complications, whereas neurosurgeons report lower rates of complications and better improvement rate, a fact that should end the controversy. The general frequency of every kind of complication, however, is comparable to the one, reported by Wang et al.⁶¹

Discussion

The progress of CM differs among patients. In some cases it follows step-wise way; in other there is an improvement or stabilization and worsening after years. Many studies have

been made to evaluate the outcome and the postoperative improvement in the patients with CM. More of them suggest a quite better outcome, but the data collected from different studies and trials would be never sufficient to establish a constant result for the postoperative quality of the patients with CM.⁶² In general, it is believed that the degree of improvement after surgery and the level of functionality depend on the severity of the disease and the time of the surgery and much from the neurological recovery.^{1,63} Decompression procedure results in stabilization or improvement in long-tract spinal cord function.⁶³ As expected, the function is better in patients who have good reinstatement of spinal canal dimensions, those without substantial comorbidity, and those who have earlier decompression surgery. For this reason, the authors have come to the conclusion that for the outcome, an important role is played by the surgeon, who performed the procedure.

Recent study by Witiw et al⁶⁴ states that patients' health is generally improved by surgical therapy for CM. The advantages of the anterior approach, however, are thought to be the better improving rate, the more direct approach to the pathology, better stabilization, and better clinical results.⁶⁵ Corpectomy is believed furthermore to be prevalent in those findings. Patient's recovery rate after anterior corpectomy with or without fusion is reported in every study and seems to be very promising. However, when comparing the both surgical teams, there is an estimated difference of the recovery rate's outcomes. Both are more than 50%, but neurosurgeons seem to be dominant, which could be explained by comparing the training program of both specialties and the used techniques.

In many of the studies are added factors that accompany the improvement of the patients. Arnold et al⁶⁶ reported that the studied patients improved after surgery, but the outcome is linked to the tobacco use and smokers have lower result compared with nonsmokers. According to studies by Cheng et al⁶³ and Rao et al,⁶⁷ the postoperative recovery is highly dependable on the age, health status, pathology, and the mode of the surgery. Rao et al pointed the age-related fallout with the myelinated fibers and motor neurons of the spinal cord, and it has been proposed that earlier surgery can improve the neurologic recovery much better. Machino et al⁶⁸ showed through the recovery rate the values of the postoperative JOA compared with the pre-JOA score, indicating that the recovery depends strongly on the age group, but the score in general do not differ much among groups.

On the other hand, researches by Fehling⁶⁹ and Liu⁷⁰ suggest general improvement in the functional quality of life and status result after surgery no matter the severity of the disease at first as well as the underlying factors. The only "must" that was mentioned, was the appropriate surgical approach. For this reason, it is important the operation be performed by qualified surgeons. This study shows that neurosurgeons have prevalence regarding the improvement rate after corpectomy, except of the cases of fibula graft. This could be explained better by the fact that the routine of the general orthopaedic team is wider (whole skeletomuscular system), whereas the routine of the general neurosurgeons is more limited. Last but not least, the general complication

rate of the orthopaedics in this study is higher than the same rate of the neurosurgeons. However, once again because of the everyday practice routine, the complications regarding grafting are lower in the orthopaedic team, whereas the complications from fine structures are lower in neurosurgeons. For this reason, the reviewers believe that the outcome of the CM is, to some extent, dependable on the operating team. The authors believe that future improvement of this subject could be achieved with the cooperation of the both sites, as it is organized in many medical centers worldwide.

Conclusion

CM is multifactor disease resulting in nerve, cord, and vascular dysfunction. Operative treatment of this condition can seriously improve the patient's condition. Not only does it enhance the neurologic function, but it also relieves the pain that the patient experiences. Concluding from different studies and researches, surgical treatment of CM cannot only restrict further worsening of the condition for a certain period, but it also can improve patients' quality of life. For this reason, the surgical team, who would perform the surgery, is very important

Conflict of Interest

None.

References

- 1 Emery SE. Cervical spondylotic myelopathy: diagnosis and treatment. *J Am Acad Orthop Surg* 2001;9(6):376-388
- 2 Rhee JM, Shamji MF, Erwin WM, et al. Nonoperative management of cervical myelopathy: a systematic review. *Spine* 2013;38(22, Suppl 1):S55-S67
- 3 Komotar RJ, Mocco J, Kaiser MG. Surgical management of cervical myelopathy: indications and techniques for laminectomy and fusion. *Spine J* 2006;6(6, Suppl):252S-267S
- 4 Lao L, Zhong G, Li X, Qian L, Liu Z. Laminoplasty versus laminectomy for multi-level cervical spondylotic myelopathy: a systematic review of the literature. *J Orthop Surg* 2013;8:45
- 5 Geck MJ, Eismont FJ. Surgical options for the treatment of cervical spondylotic myelopathy. *Orthop Clin North Am* 2002;33(2):329-348
- 6 Emery SE. Anterior approaches for cervical spondylotic myelopathy: which? When? How? *Eur Spine J* 2015;24(Suppl 2):150-159
- 7 Yalamanchili PK, Vives MJ, Chaudhary SB. Cervical spondylotic myelopathy: factors in choosing the surgical approach. *Adv Orthop* 2012;2012:783762
- 8 Hussain M, Nassr A, Natarajan RN, An HS, Andersson GB. Corpectomy versus discectomy for the treatment of multilevel cervical spine pathology: a finite element model analysis. *Spine J* 2012;12(5):401-408
- 9 Uribe JS, Sangala JR, Duckworth EA, Vale FL. Comparison between anterior cervical discectomy fusion and cervical corpectomy fusion using titanium cages for reconstruction: analysis of outcome and long-term follow-up. *Eur Spine J* 2009;18(5):654-662
- 10 Williams KE, Paul R, Dewan Y. Functional outcome of corpectomy in cervical spondylotic myelopathy. *Indian J Orthop* 2009;43(2):205-209
- 11 Fehlings MG, Arvin B. Surgical management of cervical degenerative disease: the evidence related to indications, impact, and outcome. *J Neurosurg Spine* 2009;11(2):97-100

- 12 Zairi F, Aboukais R, Thines L, Allaoui M, Assaker R. Relevance of expandable titanium cage for the treatment of cervical spondylotic myelopathy. *Eur Spine J* 2012;21(8):1545–1550
- 13 Acosta FL Jr, Aryan HE, Chou D, Ames CP. Long-term biomechanical stability and clinical improvement after extended multilevel corpectomy and circumferential reconstruction of the cervical spine using titanium mesh cages. *J Spinal Disord Tech* 2008;21(3):165–174
- 14 Shaker AS, Addosooki AI, El-Deen MA. Anterior cervical corpectomy with free vascularized fibular graft versus multilevel discectomy and grafting for cervical spondylotic myelopathy. *Int J Spine Surg* 2015;9:60
- 15 Koç RK, Menkü A, Akdemir H, Tucer B, Kurtsoy A, Oktem IS. Cervical spondylotic myelopathy and radiculopathy treated by oblique corpectomies without fusion. *Neurosurg Rev* 2004;27(4):252–258
- 16 Naderi S, Alberstone CD, Rupp FW, Benzel EC, Baldwin NG. Cervical spondylotic myelopathy treated with corpectomy: technique and results in 44 patients. *Neurosurg Focus* 1996;1(6):e5, discussion 1, e5
- 17 Aramomi M, Masaki Y, Koshizuka S, et al. Anterior pedicle screw fixation for multilevel cervical corpectomy and spinal fusion. *Acta Neurochir (Wien)* 2008;150(6):575–582, discussion 582
- 18 Shibuya S, Komatsubara S, Oka S, Kanda Y, Arima N, Yamamoto T. Differences between subtotal corpectomy and laminoplasty for cervical spondylotic myelopathy. *Spinal Cord* 2010;48(3):214–220
- 19 Thakar S, Mohan D, Furtado SV, et al. Paraspinal muscle morphometry in cervical spondylotic myelopathy and its implications in clinicoradiological outcomes following central corpectomy: clinical article. *J Neurosurg Spine* 2014;21(2):223–230
- 20 Lee HY, Lee SH, Son HK, et al. Comparison of multilevel oblique corpectomy with and without image guided navigation for multi-segmental cervical spondylotic myelopathy. *Comput Aided Surg* 2011;16(1):32–37
- 21 Chibbaro S, Benvenuti L, Carneseccchi S, et al. Anterior cervical corpectomy for cervical spondylotic myelopathy: experience and surgical results in a series of 70 consecutive patients. *J Clin Neurosci* 2006;13(2):233–238
- 22 Lin Q, Zhou X, Wang X, Cao P, Tsai N, Yuan W. A comparison of anterior cervical discectomy and corpectomy in patients with multilevel cervical spondylotic myelopathy. *Eur Spine J* 2012;21(3):474–481
- 23 Costa F, Tomei M, Sassi M, et al. Evaluation of the rate of decompression in anterior cervical corpectomy using an intra-operative computerized tomography scan (O-Arm system) *Eur Spine J* 2012;21(2):359–363
- 24 Rocchi G, Caroli E, Salvati M, Delfini R. Multilevel oblique corpectomy without fusion: our experience in 48 patients. *Spine* 2005;30(17):1963–1969
- 25 Turel MK, Sarkar S, Prabhu K, Daniel RT, Jacob KS, Chacko AG. Reduction in range of cervical motion on serial long-term follow-up in patients undergoing oblique corpectomy for cervical spondylotic myelopathy. *Eur Spine J* 2013;22(7):1509–1516
- 26 Chang HC, Tu TH, Chang HK, et al. Hybrid corpectomy and disc arthroplasty for cervical spondylotic myelopathy caused by ossification of posterior longitudinal ligament and disc herniation. *World Neurosurg* 2016;95:22–30
- 27 Gao R, Yang L, Chen H, Liu Y, Liang L, Yuan W. Long term results of anterior corpectomy and fusion for cervical spondylotic myelopathy. *PLoS One* 2012;7(4):e34811
- 28 Huang JJ, Niu CC, Chen LH, Lai PL, Fu TS, Chen WJ. Anterior cervical spinal surgery for multilevel cervical myelopathy. *Chang Gung Med J* 2004;27(7):531–541
- 29 Yang X, Chen Q, Liu L, et al. Comparison of anterior cervical fusion by titanium mesh cage versus nano-hydroxyapatite/polyamide cage following single-level corpectomy. *Int Orthop* 2013;37(12):2421–2427
- 30 Liu J, Chen X, Liu Z, Long X, Huang S, Shu Y. Anterior cervical discectomy and fusion versus corpectomy and fusion in treating two-level adjacent cervical spondylotic myelopathy: a minimum 5-year follow-up study. *Arch Orthop Trauma Surg* 2015;135(2):149–153
- 31 Lau D, Chou D, Mummaneni PV. Two-level corpectomy versus three-level discectomy for cervical spondylotic myelopathy: a comparison of perioperative, radiographic, and clinical outcomes. *J Neurosurg Spine* 2015;23(3):280–289
- 32 Ozer AF, Oktenoglu T, Cosar M, Sasani M, Sarioglu AC. Long-term follow-up after open-window corpectomy in patients with advanced cervical spondylosis and/or ossification of the posterior longitudinal ligament. *J Spinal Disord Tech* 2009;22(1):14–20
- 33 Yan D, Wang Z, Deng S, Li J, Soo C. Anterior corpectomy and reconstruction with titanium mesh cage and dynamic cervical plate for cervical spondylotic myelopathy in elderly osteoporosis patients. *Arch Orthop Trauma Surg* 2011;131(10):1369–1374
- 34 Fengbin Y, Jinhao M, Xinyuan L, Xinwei W, Yu C, Deyu C. Evaluation of a new type of titanium mesh cage versus the traditional titanium mesh cage for single-level, anterior cervical corpectomy and fusion. *Eur Spine J* 2013;22(12):2891–2896
- 35 Mao N, Wu J, Zhang Y, et al. A comparison of anterior cervical corpectomy and fusion combined with artificial disc replacement and cage fusion in patients with multilevel cervical spondylotic myelopathy. *Spine* 2015;40(16):1277–1283
- 36 Duzkalir AH, Istemen I, Okutan MO, Ozdogan S, Senturk S, Yildirim T. Clinical results of median corpectomy in cervical spondylotic patients with myelopathy. *Turk Neurosurg* 2014;26(1):1–8
- 37 Epstein NE. Reoperation rates for acute graft extrusion and pseudarthrosis after one-level anterior corpectomy and fusion with and without plate instrumentation: etiology and corrective management. *Surg Neurol* 2001;56(2):73–80, discussion 80–81
- 38 Epstein NE, Silvergleide RS. Documenting fusion following anterior cervical surgery: a comparison of roentgenogram versus two-dimensional computed tomographic findings. *J Spinal Disord Tech* 2003;16(3):243–247
- 39 Ernestus RI, Koehler S, Raslan F, Rueckriegel SM, Stetter C, Westermaier T. Autologous bone graft versus PEKK cage for vertebral replacement after 1- or 2-level anterior median corpectomy. *J Neurosurg Spine* 2016;24:309–314
- 40 Niu CC, Hai Y, Fredrickson BE, Yuan HA. Anterior cervical corpectomy and strut graft fusion using a different method. *Spine J* 2002;2(3):179–187
- 41 Perrini P, Gambacciani C, Martini C, Montemurro N, Lepori P. Anterior cervical corpectomy for cervical spondylotic myelopathy: reconstruction with expandable cylindrical cage versus iliac crest autograft. A retrospective study. *Clin Neurol Neurosurg* 2015;139:258–263
- 42 Li Z, Guo Z, Hou S, et al. Segmental anterior cervical corpectomy and fusion with preservation of middle vertebrae in the surgical management of 4-level cervical spondylotic myelopathy. *Eur Spine J* 2014;23(7):1472–1479
- 43 Gupta A, Rajshekhar V. Functional and radiological outcome in patients undergoing three level corpectomy for multi-level cervical spondylotic myelopathy and ossified posterior longitudinal ligament. *Neurol India* 2016;64(1):90–96
- 44 Lu T, Liu C, Yang B, et al. Single-level anterior cervical corpectomy and fusion using a new 3D-printed anatomy-adaptive titanium mesh cage for treatment of cervical spondylotic myelopathy and ossification of the posterior longitudinal ligament: a retrospective case series study. *Med Sci Monit* 2017;23:3105–3114

- 45 Li Z, Huang J, Zhang Z, Li F, Hou T, Hou S. A comparison of multilevel anterior cervical discectomy and corpectomy in patients with 4-level cervical spondylotic myelopathy: a minimum 2-year follow-up study: multilevel anterior cervical discectomy. *Clin Spine Surg* 2017;30(5):E540–E546
- 46 Liu Y, Yu KY, Hu JH. Hybrid decompression technique and two-level corpectomy are effective treatments for three-level cervical spondylotic myelopathy. *J Zhejiang Univ Sci B* 2009;10(9):696–701
- 47 Tateiwa Y, Kamimura M, Itoh H, et al. Multilevel subtotal corpectomy and interbody fusion using a fibular bone graft for cervical myelopathy due to ossification of the posterior longitudinal ligament. *J Clin Neurosci* 2003;10(2):199–207
- 48 Zhang Y, Quan Z, Zhao Z, et al. Evaluation of anterior cervical reconstruction with titanium mesh cages versus nano-hydroxyapatite/polyamide66 cages after 1- or 2-level corpectomy for multilevel cervical spondylotic myelopathy: a retrospective study of 117 patients. *PLoS One* 2014;9(5):e96265
- 49 Wada E, Suzuki S, Kanazawa A, Matsuoka T, Miyamoto S, Yonenobu K. Subtotal corpectomy versus laminoplasty for multilevel cervical spondylotic myelopathy: a long-term follow-up study over 10 years. *Spine* 2001;26(13):1443–1447, discussion 1448
- 50 Kristof RA, Kiefer T, Thudium M, et al. Comparison of ventral corpectomy and plate-screw-instrumented fusion with dorsal laminectomy and rod-screw-instrumented fusion for treatment of at least two vertebral-level spondylotic cervical myelopathy. *Eur Spine J* 2009;18(12):1951–1956
- 51 Kimura H, Shikata J, Odate S, Soeda T. Anterior corpectomy and fusion to C2 for cervical myelopathy: clinical results and complications. *Eur Spine J* 2014;23(7):1491–1501
- 52 Odate S, Shikata J, Kimura H, Soeda T. Hybrid decompression and fixation technique versus plated 3-vertebra corpectomy for 4-segment cervical myelopathy: analysis of 81 cases with a minimum 2-year follow-up. *Clin Spine Surg* 2016;29(6):226–233
- 53 Kotil K, Tari R. Two level cervical corpectomy with iliac crest fusion and rigid plate fixation: a retrospective study with a three-year follow-up. *Turk Neurosurg* 2011;21(4):606–612
- 54 Kumar GS, Rajshekhar V. Acute graft extrusion following central corpectomy in patients with cervical spondylotic myelopathy and ossified posterior longitudinal ligament. *J Clin Neurosci* 2009;16(3):373–377
- 55 Lu J, Wu X, Li Y, Kong X. Surgical results of anterior corpectomy in the aged patients with cervical myelopathy. *Eur Spine J* 2008;17(1):129–135
- 56 Vedantam A, Revanappa KK, Rajshekhar V. Changes in the range of motion of the cervical spine and adjacent segments at ≥ 24 months after uninstrumented corpectomy for cervical spondylotic myelopathy. *Acta Neurochir (Wien)* 2011;153(5):995–1001
- 57 Fessler RC, Steck JC, Giovanini MA. Anterior cervical corpectomy for cervical spondylotic myelopathy. *Neurosurgery* 1998;43(2):257–265, discussion 265–267
- 58 George B, Gauthier N, Lot G. Multisegmental cervical spondylotic myelopathy and radiculopathy treated by multilevel oblique corpectomies without fusion. *Neurosurgery* 1999;44(1):81–90
- 59 Saunders RL, Bernini PM, Shirreffs TG Jr, Reeves AG. Central corpectomy for cervical spondylotic myelopathy: a consecutive series with long-term follow-up evaluation. *J Neurosurg* 1991;74(2):163–170
- 60 Lian XF, Xu JG, Zeng BF, Zhou W, Kong WQ, Hou TS. Noncontiguous anterior decompression and fusion for multilevel cervical spondylotic myelopathy: a prospective randomized control clinical study. *Eur Spine J* 2010;19(5):713–719
- 61 Wang T, Tian XM, Liu SK, Wang H, Zhang YZ, Ding WY. Prevalence of complications after surgery in treatment for cervical compressive myelopathy: a meta-analysis for last decade. *Medicine (Baltimore)* 2017;96(12):e6421
- 62 Ying Z, Xinwei W, Jing Z, et al. Cervical corpectomy with preserved posterior vertebral wall for cervical spondylotic myelopathy: a randomized control clinical study. *Spine* 2007;32(14):1482–1487
- 63 Cheng SC, Yen CH, Kwok TK, Wong WC, Mak KH. Anterior spinal fusion versus laminoplasty for cervical spondylotic myelopathy: a retrospective review. *J Orthop Surg (Hong Kong)* 2009;17(3):265–268
- 64 Witiw CD, Tetreault LA, Smieliauskas F, Kopjar B, Massicotte EM, Fehlings MG. Surgery for degenerative cervical myelopathy: a patient-centered quality of life and health economic evaluation. *Spine J* 2017;17(1):15–25
- 65 Liu T, Xu W, Cheng T, Yang HL. Anterior versus posterior surgery for multilevel cervical myelopathy, which one is better? A systematic review. *Eur Spine J* 2011;20(2):224–235
- 66 Arnold PM, Kopjar B, Tetreault L, Nakashima H, Fehlings MG. 162 Tobacco smoking and outcomes of surgical decompression in patients with symptomatic degenerative cervical spondylotic myelopathy. *Neurosurgery* 2016;63(Suppl 1):165
- 67 Rao RD, Gourab K, David KS. Operative treatment of cervical spondylotic myelopathy. *J Bone Joint Surg Am* 2006;88(7):1619–1640
- 68 Machino M, Yukawa Y, Hida T, et al. Can elderly patients recover adequately after laminoplasty?: a comparative study of 520 patients with cervical spondylotic myelopathy. *Spine* 2012;37(8):667–671
- 69 Fehlings MG, Wilson JR, Kopjar B, et al. Efficacy and safety of surgical decompression in patients with cervical spondylotic myelopathy: results of the AOSpine North America prospective multi-center study. *J Bone Joint Surg Am* 2013;95(18):1651–1658
- 70 He X, Li H, Liu J, Xu S, Zhang L. The surgical approaches of cervical spondylotic myelopathy and the predictive factors for the surgical outcome. *Int J Clin Med* 2011;2(2):158–165